




available at www.sciencedirect.com



journal homepage: www.elsevier.com/locate/psyneuen



Organizational effects of fetal testosterone on human corpus callosum size and asymmetry

Lindsay R. Chura^{a,1,*}, Michael V. Lombardo^{a,1}, Emma Ashwin^a,
Bonnie Auyeung^a, Bismadev Chakrabarti^{a,b}, Edward T. Bullmore^c,
Simon Baron-Cohen^{a,*}

^a Autism Research Centre, Department of Psychiatry, University of Cambridge, Cambridge, UK

^b Department of Psychology, University of Reading, UK

^c Brain Mapping Unit, Department of Psychiatry, University of Cambridge, UK

Received 6 May 2009; received in revised form 9 September 2009; accepted 10 September 2009

KEYWORDS

Fetal testosterone;
Corpus callosum;
Asymmetry;
Brain development;
Organizational effects

Summary Previous theory and research in animals has identified the critical role that fetal testosterone (FT) plays in organizing sexually dimorphic brain development. However, to date there are no studies in humans directly testing the organizational effects of FT on structural brain development. In the current study we investigated the effects of FT on corpus callosum size and asymmetry. High-resolution structural magnetic resonance images (MRI) of the brain were obtained on 28 8–11-year-old boys whose exposure to FT had been previously measured *in utero* via amniocentesis conducted during the second trimester. Although there was no relationship between FT and midsagittal corpus callosum size, increasing FT was significantly related to increasing rightward asymmetry (e.g., Right > Left) of a posterior subsection of the callosum, the isthmus, that projects mainly to parietal and superior temporal areas. This potential organizational effect of FT on rightward callosal asymmetry may be working through enhancing the neuroprotective effects of FT and result in an asymmetric distribution of callosal axons. We suggest that this possible organizational effect of FT on callosal asymmetry may also play a role in shaping sexual dimorphism in functional and structural brain development, cognition, and behavior.

© 2009 Elsevier Ltd. All rights reserved.

1. Introduction

Sexual dimorphism of the brain in both animals and humans has been the focus of much research and contentious popular debate for more than a century (Broca, 1861; Bean, 1906; Mall, 1909; Beach, 1948; Goy and McEwen, 1980; MacLusky and Naftolin, 1981; Geschwind and Galaburda, 1987; Witelson, 1989, 1991; Witelson and Nowakowski, 1991; Giedd et al., 1996; Good et al., 2001; Sowell et al., 2007). Within

* Corresponding authors.

E-mail addresses: lrc36@cam.ac.uk (L.R. Chura),
m437@cam.ac.uk (M.V. Lombardo), sb205@cam.ac.uk
(S. Baron-Cohen).

¹ These authors contributed equally to this work.

this body of research, the corpus callosum (CC) has generated considerable interest. As the brain's largest white matter tract and main interhemispheric commissure, the callosum is comprised of approximately 200 million fibers (Tomasch, 1954; LaMantia and Rakic, 1990a; Aboitiz et al., 1992a) connecting the two hemispheres and facilitates the rapid transfer of information between homotopic (Sperry, 1982) and heterotopic cortical areas (Witelson, 1989). Rather than being one homogenous bundle of fibers, subsections of the callosum vary dramatically in quantitative characteristics of axon density, size, and degree of myelination (LaMantia and Rakic, 1990b). Subsections of the macaque CC also reflect an underlying topographic organization in its connectivity with the cerebral cortex (Pandya et al., 1971), with the most anterior regions projecting mainly to prefrontal cortex, anterior mid-regions projecting to premotor and supplementary motor areas, mid-posterior sections projecting to primary and secondary sensorimotor regions, and the most posterior regions projecting to posterior parietal, temporal, and occipital areas. Whilst finer autoradiographic tracer techniques in animals cannot be done in humans, *in vivo* tractography-based segmentation of the CC using diffusion tensor imaging suggests a slightly shifted, yet similar topographic organization (Hofer and Frahm, 2006). The male macaque and rat CC also appears to be larger or has a higher density of axons (around 10 million more) than females (Berrebi et al., 1988; LaMantia and Rakic, 1990b). However, sexual dimorphism of the human CC is a topic of more contentious debate.

Controversy over sexual dimorphism in the human CC dates back to 1906 when anatomist R.B. Bean first suggested that males had a larger CC than females (Bean, 1906). However, in 1909, Franklin Mall, director of the lab in which Bean worked, dismissed these claims, noting no such differences between sexes (Mall, 1909). Eight decades later, DeLacoste-Utamsing and Holloway revived the controversy with the finding of sexual dimorphism in the posterior subsection of the CC, known as the splenium (DeLacoste-Utamsing and Holloway, 1982). While later studies extended these findings (DeLacoste-Utamsing and Holloway, 1982; Holloway and de Lacoste, 1986; de Lacoste et al., 1986; Allen et al., 1991; Holloway et al., 1993), showing that the female splenium was more bulbous and larger than the cylindrically shaped male splenium, other investigations yielded contrary results (Witelson, 1985, 1989; Byne et al., 1988; Clarke et al., 1989; Going and Dixson, 1990). A meta-analysis of 49 studies examining sex differences in the CC found no sexual dimorphism in the size or shape of the splenium, even when covarying for whole-brain size (Bishop and Wahlsten, 1997). However, all of these studies compare the size of the CC from a sample along the *midsagittal* section. Only one study to date has compared *parasagittal* size and asymmetry (i.e. offset from the midsagittal slice), and this study found increased rightward callosal asymmetry (e.g., Right > Left) in males compared to females (Luders et al., 2006). This finding is important since it demonstrates that there may be more to sexually dimorphic organization of the CC than just midsagittal size. Sexual dimorphism of the CC may also involve *asymmetric* hemispheric development and can be reflected in the distribution of parasagittal callosal fibers.

Sexual dimorphism in the CC may also relate to notable sexual dimorphisms in hemispheric asymmetry. Pioneering

ideas developed by Geschwind (Geschwind and Behan, 1982; Geschwind and Galaburda, 1985a,b, 1987) and Witelson (Witelson, 1991; Witelson and Nowakowski, 1991) have been influential in proposing underlying mechanisms for such asymmetry. Geschwind suggested the role of fetal testosterone (FT) as a mechanism underlying altered brain development and the observed patterns of functional asymmetric dominance in handedness, visuospatial skills, and language. Geschwind's hypothesis specifically predicts that increasing exposure to FT during critical periods of fetal brain development slows the maturation of the left hemisphere, thus allowing the right hemisphere to achieve dominance. The delayed development of left hemisphere functions in males would explain many of the observed trends: accelerated language development in females, enhanced performance in males during visuospatial tasks, and the increased rate of left-handedness in males. Witelson (Witelson, 1991; Witelson and Nowakowski, 1991) proposed a different mechanism to Geschwind, with her 'callosal hypothesis', which suggests that functional asymmetry is due to the asymmetric pattern of callosal axon pruning during fetal and neonatal development. While these two hypotheses differ regarding hypothesized mechanisms (delayed left hemisphere development vs. asymmetric callosal axon pruning), such mechanisms are not necessarily in opposition with one another. Both could play a part in causing asymmetric development. For example, delayed left hemisphere development may be apparent in asymmetric patterns of callosal axon pruning. Furthermore, despite mechanistic differences, both theories posit FT as one common biological substrate that may be responsible for influencing these sexually dimorphic patterns of brain development.

Animal studies provide initial support that early exposure to FT has 'organizational effects' (Beach, 1948; Phoenix et al., 1959; Arnold and Breedlove, 1985) in establishing normative cortical asymmetry and callosal sexual dimorphism. In rats, the general observation of asymmetric Right > Left cortical thickness can be eliminated by gonadectomy at birth (Stewart and Kolb, 1988). Furthermore, prenatal stress has been found to abnormally shift the peak of the FT surge *in utero* (Ward and Weisz, 1980). Such shifts in FT surges prevent the normative development of rightward asymmetry in cortical thickness (Fleming et al., 1986). The CC in rats also tends to be larger in males than females (Berrebi et al., 1988). However, manipulation of FT through prenatal stress or prenatal androgen blockage eliminates this sexual dimorphism of the CC (Zimmerberg and Scalzi, 1989; Fitch et al., 1991).

Despite such evidence for the organizational effects of FT on brain development in non-human species, no studies in humans have directly tested the effects of FT on cerebral asymmetry or callosal development. So far only indirect measures of FT (such as the influence of sharing the intrauterine environment with a dizygotic male twin) suggest that FT may play an organizing role in human structural brain development (Peper et al., 2009b). In the present study, we test for the first time, the direct effects of FT on the human corpus callosum. Our goals were twofold. First, we aimed to test whether individual differences in the size of the human CC are related to FT. Given that exposure to higher levels of FT is one of the marked differences between males and females during critical periods of fetal brain development, we predicted that FT would be significantly related to the size

of the CC (or any of its subsections) in typically developing boys. Second, we aimed to evaluate both Geschwind's and Witelson's hypotheses in relation to sexually dimorphic rightward parasagittal callosal asymmetry, first documented by Luders et al. (2006). Our prediction was that if increased FT levels lead to rightward asymmetric development of the brain, we should expect that FT levels would predict increasing rightward parasagittal callosal asymmetry.

To test these hypotheses we conducted high-resolution structural magnetic resonance imaging (sMRI) on 28 typically developing boys for whom we have measurements of FT that were collected during gestation. Region-of-interest methods were used to obtain measurements of callosal size and asymmetry and standard measures of CC partitioning were used to divide the CC into subsections based on its connectivity with the rest of the cerebral cortex.

2. Methods

2.1. Participants

Participants were recruited from a longitudinal study of the effects of FT on cognitive, behavioral, and brain development (Baron-Cohen et al., 2004). Initial screening consisted of reviewing medical records of patients who underwent amniocentesis in the Cambridgeshire (UK) region between 1996 and 1999. Individuals were excluded if: (a) the amniocentesis revealed a chromosomal abnormality; (b) there was a twin pregnancy; (c) the pregnancy ended in termination or miscarriage; (d) relevant information was absent from the medical records; (e) medical practitioners indicated it would be inappropriate to contact the family. Any child that presented with any developmental abnormalities postnatally was also excluded from testing. The final set of participants were 28 right-handed typically developing boys (mean age = 9.5, SD = 0.92, range, 8–11; see Table 1). Informed consent was obtained from all the participant's legal guardians in accordance with procedures approved by the Local Research Ethics Committee.

2.2. Fetal testosterone collection and measurement

Fetal testosterone was measured from amniotic fluid samples collected between 13 and 20 weeks of gestation (see Table 1). This is within the period of 8–24 weeks of gestation which coincides with the hypothesized critical period for human sexual differentiation (Hines, 2004). Seven participants from the sample had missing data with regards to the exact time of amniocentesis. However, analysis of the

remaining 21 participants showed that there was no linear or quadratic relationship between gestational age at which FT was sampled and FT level ($r = 0.12$, $p = 0.60$), confirming prior work showing an absence of a relationship (Grimshaw et al., 1995a; Chapman et al., 2006; Auyeung et al., 2009).

FT was assayed via radioimmunoassay. Amniotic fluid was extracted with diethyl ether, which was evaporated to dryness at room temperature and the extracted material redissolved in an assay buffer. Testosterone was assayed by the DPC 'Count-a-Coat' method (Diagnostic Product Corp, Los Angeles, CA, USA), which uses an antibody to testosterone coated onto propylene tubes and a 125-I labelled testosterone analogue. The detection limit of the assay using the ether-extraction method is approximately 0.05 nmol/l. The coefficient of variation (CV) for between batch imprecision is 19% at a concentration of 0.8 nmol/l and 9.5% at a concentration of 7.3 nmol/l. The CV's for within batch imprecision are 15% at a concentration of 0.3 nmol/l and 5.9% at a concentration of 2.5 nmol/l. This method measures total extractable testosterone.

2.3. MRI acquisition

All imaging took place at the Wolfson Brain Imaging Centre at Addenbrooke's Hospital, Cambridge, UK on a Siemens Tim Trio 3 Tesla magnet (Siemens Medical Solutions, AG, Erlangen, Germany). High-resolution T1-weighted three-dimensional magnetization-prepared rapid acquisition gradient-echo (MP-RAGE) structural images were acquired with the following parameters: slice thickness = 1 mm; TR = 2300 ms; TE = 2.98 ms; field of view = 256 mm × 240 mm × 176 mm; flip angle = 9°; voxel size = 1 mm³ isotropic.

2.4. Image processing

Each image was segmented using the VBM5 toolbox (<http://dbm.neuro.uni-jena.de/vbm/>) within SPM5 without the use of spatial tissue probability priors. Total volume of gray, white, and CSF matter was automatically computed from this procedure and total intracranial volume was computed as the sum of gray, white and CSF matter. Next, the midsagittal slice was identified by finding the interhemispheric fissure in the coronal and sagittal planes. Once at the midsagittal slice, each image was manually reoriented such that a horizontal line could be seen visibly intersecting through the most anterior and posterior points of the CC on the midsagittal slice. The entire CC was then traced manually on the midsagittal slice using the MRICron software package (<http://www.sph.sc.edu/comd/rorden/mricron/>). In addition to the midsagittal region-of-interest (ROI), parasagittal ROIs were also drawn in the left and right hemisphere. This procedure was similar to the procedure followed by Luders et al., 2006. From the midsagittal slice, the rater moved over 6 slices (e.g., 6 mm from the midsagittal slice) on either side of the midsagittal slice. If the CC could be clearly traced 6 slices from the midsagittal slice in both hemispheres, then these were the parasagittal ROIs. However, in the instance where the CC could not be clearly traced 6 mm from midline, the rater moved back one slice towards the midline and then re-evaluated if the CC could be clearly traced here. If the CC could still not be clearly traced, this procedure was repeated until the rater found a slice that could be unambiguously

Table 1 Demographic information (n = 28).

Variable	Mean	SD	Range
Fetal testosterone (nmol/l)	0.79	0.34	0.25–1.70
Age (years)	9.50	0.92	8–11
Gestational age at amniocentesis (weeks) ^a	16.37	1.33	14–19

^a Data only available for a subset of children (n = 21).

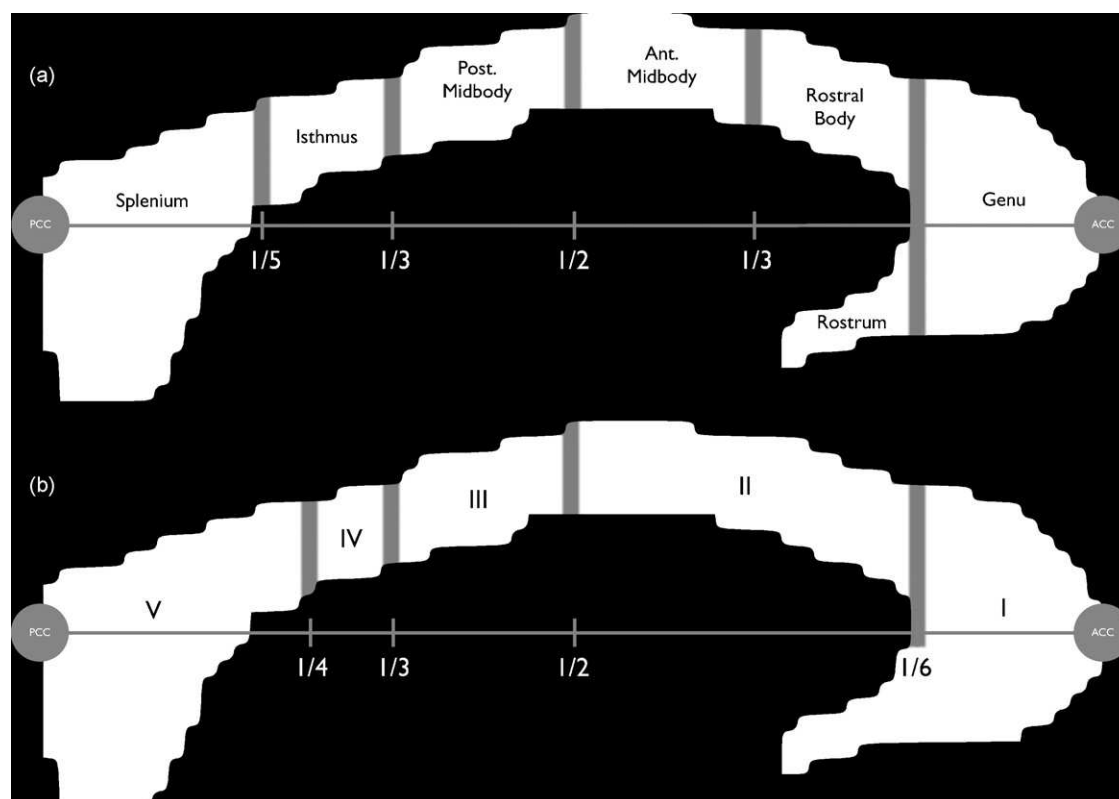


Fig. 1 Corpus callosum subsection partitions. Panel (a) depicts the Witelson method for partitioning subsections of the corpus callosum. This method is derived mainly from experimental work in monkeys (Witelson, 1989). Panel (b) depicts the Hofer–Frahm method for partitioning subsections of the corpus callosum. This method differs from the Witelson method mainly in that it is derived from *in vivo* work in humans, using DTI tractography-based segmentation as a way of dividing the corpus callosum based on its connections with the cortex (Hofer and Frahm, 2006). ACC: anterior corpus callosum; PCC: posterior corpus callosum.

traced. When a parasagittal slice was identified, the distance in slices from the midsagittal slice was noted, and the same distance was used when drawing the other parasagittal ROI in the opposite hemisphere. Two of the authors (LRC and MVL) traced the entire dataset and inter-rater reliability (intra-class correlation averaged across all ROIs) was $r = 0.98$.

2.5. Area measurements

After tracing the ROIs, all area measurements were computed using custom Matlab scripts written by MVL in Matlab 7.1 (<http://www.mathworks.com/>). The script read each ROI into Matlab as a binary mask of 0 or 1, where voxel values were 1 if they were inside the ROI and 0 if they are outside the ROI. Since native voxel resolution was 1 mm^3 , the area measurement was a simple calculation of the number of voxels within the ROI. Once each total area measurement was made for each ROI (midsagittal, left, and right), the midsagittal and parasagittal ROIs were partitioned using two methods: (1) The straight-line method of partitioning the corpus callosum described by (Witelson, 1989); and (2) The Hofer–Frahm method (Hofer and Frahm, 2006). While both the Witelson and Hofer–Frahm method use geometrically defined cut-off points, Witelson’s boundaries were derived from criteria based mostly on experimental work in *monkeys* while those obtained via the Hofer–Frahm method were derived from *in vivo* tractography-based segmentation of

the CC using diffusion tensor imaging in *humans*. See Fig. 1 for a schematic of how the CC subsections were partitioned under each method, and see Table 2 for reference to the criteria for how each subsection was partitioned based on its projections (connectivity) to the cerebral cortex.

2.6. Data analysis

To evaluate the effects of FT on CC size, all analyses were hierarchical multiple regressions where age, total intracranial volume, and FT were the independent variables. The dependent variables in these analyses were total CC area or area of subsections of the CC on the midsagittal ROI. Similar multiple regressions were done on total gray and white matter, although these analyses excluded intracranial volume as an independent variable.

We also ran analyses to evaluate asymmetries in CC size. To do this, we computed an asymmetry index as the difference score between right and left parasagittal ROIs (Right–Left). Positive scores on this index indicate a Right > Left difference, while negative scores indicated a Left > Right difference. Scores near 0 indicated that Right = Left. Multiple regression analyses were then run again using asymmetry index scores as the dependent variable and age, total intracranial volume, and FT as the independent variables. All analyses were re-run using gestational age as a covariate in the subsample of 21 children for which such data was

Table 2 Description of anatomical subsections of the corpus callosum and the regions of cortex each is most highly connected with.

Method	Anatomical Label	Connectivity
Witelson	Rostrum	Caudal/orbital prefrontal, inferior premotor cortex
	Genu	Prefrontal cortex
	Rostral body	Premotor, supplementary motor cortex
	Anterior midbody	Motor cortex
	Posterior midbody	Somatosensory, posterior parietal cortex
	Isthmus	Superior temporal, posterior parietal cortex
	Splenium	Occipital, inferior temporal cortex
Hofer–Frahm	I	Prefrontal cortex
	II	Premotor, supplementary motor cortex
	III	Primary motor cortex
	IV	Primary somatosensory cortex
	V	Parietal, temporal, occipital cortex

available and all results remain. Given this, and the fact that there were no relationships between gestational age of amniotic sampling and FT levels, we report the results using the full sample. For the asymmetry results, all effects were evaluated based on one-tailed significance tests, since the Geschwind hypothesis makes the specific directional prediction that FT should increase a Right > Left effect.

In all data analyses we report *p*-values and *p*-rep statistics. The *p*-rep statistic is a newer form of statistical inference which estimates the probability of replicating an effect (Killeen, 2005) and is reported for thoroughness and to supplement inferences made from standard *p*-values.

Table 3 Effects of fetal testosterone on total gray and white matter volume after covarying for age. Also shown are the effects of fetal testosterone on total midsagittal and parasagittal corpus callosum area after covarying for age and total intracranial volume.

Dependent variable	β	$r_{(partial)}$	<i>p</i> -value	<i>p</i> -rep
Total gray matter	−0.176	−0.180	0.369	0.74
Total white matter	−0.056	−0.057	0.779	0.58
Total midsagittal CC	−0.004	−0.006	0.977	0.51
Total right parasagittal CC	0.100	0.125	0.543	0.67
Total left parasagittal CC	0.003	0.004	0.983	0.51

3. Results

In the first set of analyses we set out to test whether FT is related to total gray (GM) or white matter (WM) volume. Hierarchical multiple regression analyses showed no effect of FT in predicting total GM ($r_{partial} = -0.18$, $p = 0.369$, $p\text{-rep} = 0.74$) or WM ($r_{partial} = -0.057$, $p = 0.779$, $p\text{-rep} = 0.58$). Next, we tested whether FT would be related to total area of the midsagittal or parasagittal CC ROIs. Again, FT did not significantly predict size of the CC in any of the ROIs (MS: $r_{partial} = -0.006$, $p = 0.977$, $p\text{-rep} = 0.51$; Right: $r_{partial} = 0.125$, $p = 0.543$, $p\text{-rep} = 0.67$; Left: $r_{partial} = 0.004$, $p = 0.983$, $p\text{-rep} = 0.51$). See Table 3. When broken down into subsections, again, FT did not predict size of the midsagittal CC (all approximately $0.50 < p < 0.95$). See Table 4.

In the final set of analyses we tested whether FT could predict the degree of asymmetry in the CC. To do this, we first computed asymmetry indices for the total CC, and then again on each subsection of the CC. Calculation of the asymmetry index by using ratio scores (instead of difference scores) or by using a formula provided by Luders et al. (2006) of (Left − Right)/0.5(Left + Right) revealed similar results. In other words, this asymmetry index was the difference score between right and left parasagittal ROIs (Right−Left). Thus, we report the difference scores as the measure of asymmetry index. Scores greater than 0 indicate increasing rightward

Table 4 Effects of fetal testosterone on midsagittal subsections of the corpus callosum after covarying for age and total intracranial volume.

Dependent variable	β	$r_{(partial)}$	<i>p</i> -value	<i>p</i> -rep
Witelson Splenium	−0.021	−0.025	0.903	0.53
Witelson Isthmus	0.064	0.073	0.723	0.60
Witelson post-midbody ^a	0.103	0.140	0.496	0.68
Witelson ant midbody	0.031	0.035	0.865	0.55
Witelson rostral body	0.164	0.182	0.372	0.74
Witelson genu	−0.021	−0.026	0.898	0.54
Witelson rostrum	0.02	−0.009	0.912	0.53
Hofer–Frahm Section V	−0.010	−0.012	0.952	0.52
Hofer–Frahm Section IV	0.083	0.098	0.633	0.63
Hofer–Frahm Section III ^a	0.103	0.140	0.496	0.68
Hofer–Frahm Section II	0.042	0.053	0.798	0.57
Hofer–Frahm Section I	0.025	0.029	0.889	0.54

^a Because the partitioning methods are equivalent with regards to this segment, the statistics are identical and were only computed once.

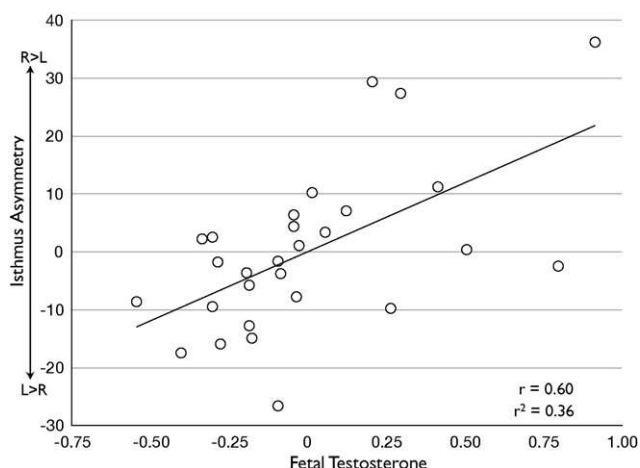


Fig. 2 FT predicts rightward asymmetry of the isthmus. This figure plots the regression residuals for the isthmus asymmetry index against fetal testosterone, after controlling for age and intracranial volume. Increasing values on the y-axis indicate more rightward asymmetry (R > L), while negative values indicate increasing leftward asymmetry (L > R). As fetal testosterone increases, the isthmus increases towards more rightward asymmetry. This relationship shows that FT predicts approximately 36% of the variance in isthmus asymmetry.

asymmetry (Right > Left), while scores less than 0 indicate increasing leftward asymmetry (Left > Right). Scores near 0 indicate relatively symmetry in the CC (Right–Left). Using the Witelson method, the isthmus was the only region showing a significant effect. FT was positively correlated with increasing rightward asymmetry of the Isthmus ($r_{\text{partial}} = 0.596$, $p_{\text{(one-tailed)}} = 6.52 \times 10^{-4}$, $p\text{-rep} = 0.99$) and accounted for approximately 36% of the variance. Similarly, an analogous region using the Hofer–Frahm method, subsection IV, was significantly related in the same direction and accounted for approximately 34% of the variance. That is, increasing rightward asymmetry of subsection IV was predicted by increasing FT levels ($r_{\text{partial}} = 0.578$, $p_{\text{(one-tailed)}} = 9.82 \times 10^{-4}$, $p\text{-rep} = 0.99$). No other regions from

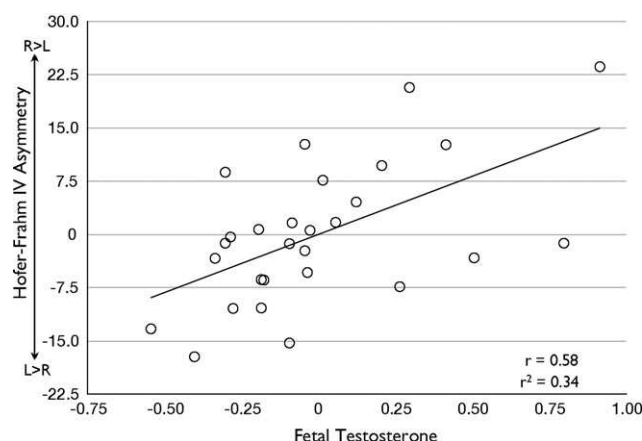


Fig. 3 FT predicts rightward asymmetry of subsection IV from the Hofer–Frahm method. This figure plots the regression residuals for the subsection IV asymmetry index against fetal testosterone, after controlling for age and intracranial volume. Increasing values on the y-axis indicate more rightward asymmetry (R > L), while negative values indicate increasing leftward asymmetry (L > R). As fetal testosterone increases, subsection IV increases towards more rightward asymmetry. This relationship shows that FT predicts approximately 34% of the variance in isthmus asymmetry.

both the Witelson or Hofer–Frahm method showed significant relationships between FT and asymmetry. See Table 5 and Figs. 2 and 3. Bonferroni correction for the 12 comparisons conducted on the asymmetry analyses results in p -values that are still significant at $p < 0.05$.

4. Discussion

4.1. FT effects on corpus callosum size

To the best of our knowledge, this is the first study to directly examine whether quantitative measures of neuroanatomical variability of the CC are influenced by FT exposure. Our first goal was to assess whether midsagittal CC size could be

Table 5 FT effects on corpus callosum asymmetry after covarying for age and total intracranial volume.

Dependent variable	β	$r_{\text{(partial)}}$	$p\text{-value}^*$	$p\text{-rep}$
Total asymmetry	0.204	0.214	0.147	0.77
Witelson splenium	-0.097	-0.107	0.302	0.64
Witelson isthmus**	0.597	0.596	6.520×10^{-4}	0.99
Witelson post-midbody ^a	0.100	0.100	0.314	0.63
Witelson ant midbody	0.154	0.162	0.215	0.71
Witelson rostral body	0.193	0.197	0.168	0.75
Witelson genu	-0.016	-0.017	0.466	0.52
Witelson rostrum	-0.011	-0.011	0.478	0.52
Hofer–Frahm Section V	0.146	0.146	0.238	0.69
Hofer–Frahm Section IV**	0.544	0.578	9.82×10^{-4}	0.99
Hofer–Frahm Section III ^a	0.100	0.100	0.314	0.63
Hofer–Frahm Section II	-0.217	-0.252	0.107	0.81
Hofer–Frahm Section I	0.213	0.266	0.095	0.82

^a Because the partitioning methods are equivalent with regards to this segment, the statistics are identical and were only computed once.

* All p -values are significance values from one-tailed tests.

** Significant at $p < 0.001$.

predicted by individual differences in FT exposure. It was our hypothesis that if the human CC is sexually dimorphic, the underlying cause for such sexual dimorphism could be related to the degree of FT exposure early in prenatal development. However, we observed no such relationship between the size of midsagittal sections of the CC and FT levels. In fact, neither total area, nor area of any subsection came close to being significantly related to FT. Thus, despite the relatively small sample size, it is unlikely that any effects are likely to appear in a larger sample size. We can conclude that midsagittal CC size is not significantly related to the degree of FT exposure.

How does this result relate to the controversy in sexual dimorphism in human CC size? This study does not directly test sexual dimorphism in the CC per se (given that the sample is entirely male). However, animal studies have shown a clear relationship between FT and cortical asymmetry and CC sexual dimorphism (Fleming et al., 1986; Stewart and Kolb, 1988; Zimmerberg and Scalzi, 1989; Fitch et al., 1991). Thus, according to the animal literature one might argue that FT may be a mechanism underlying any sexual dimorphism in midsagittal human CC size. However, we can conclude from our data that FT does not influence individual differences in the size of the midsagittal human CC as measured between 8–11 years of age. Whether or not FT does play a role in human CC sexual dimorphism during other periods of development remains an open question for future research.

4.2. FT effects on corpus callosum asymmetry

The second goal of the study was to test whether FT plays a role in asymmetric development of the CC. As the Geschwind hypothesis suggests, increased levels of FT may slow left hemisphere development and result in dominance of right hemisphere function in males (Geschwind and Galaburda, 1985a,b, 1987). In addition, a previous study noted rightward asymmetrical sexual dimorphism in parasagittal CC size (Luders et al., 2006). Given that the CC is the largest white matter tract and the main interhemispheric commissure in the brain, the CC is an ideal candidate for influencing such cerebral asymmetry (Witelson, 1991) and may do so via asymmetric pruning of callosal axons in each hemisphere early in brain development (Witelson and Nowakowski, 1991). We found that total CC asymmetry was not significantly related to FT. Similarly, across almost all subsections of the CC, we found that FT did not predict the degree of asymmetry. The only subsection showing a relationship between FT and callosal asymmetry was the region around the isthmus. Remarkably, FT independently predicted approximately 36% of the variance in asymmetry within this region. Thus, these results provide strong support for the idea that FT is a primary mechanism for lateralization of the human brain. One way in which FT may enhance this lateralization is through the observed effects on asymmetric callosal size.

4.3. FT as a neuroprotective mechanism?

The current results of FT-mediated rightward shifts in callosal asymmetry begs the question as to how FT might exert such an influence during early periods of brain development? As noted before, Witelson suggested that sex hormones may

play a role in guiding asymmetric patterns of *callosal axon pruning*, and this is a view which is supported by the current data. However, Geschwind postulated a mechanism whereby FT *delays* the development of the left hemisphere, allowing the right hemisphere to achieve dominance. The current data could also support this in conjunction with Witelson's hypothesis. A third alternative however, could be through the role of fetal androgens in promoting neuroprotective processes. Sex steroids are well known for their neuroprotective role throughout early stages of brain development and throughout later stages (e.g., demonstrated in neurodegenerative disorders such as Alzheimer's). In the current study, fetal androgens may be promoting a multitude of neuroprotective processes such as dendritic growth and axonal regeneration, among many others. For example, Yu and Srinivasan (1981) observed the effects of testosterone in promoting axonal growth following hypoglossotomy. Furthermore, Kujawa et al. (1991) showed that testosterone increases the rate of axonal regeneration after facial nerve crush axotomy. One question for future research would be to test the timing at which FT-mediated asymmetry emerges: whether surges of FT early in prenatal development promote asymmetric *overgrowth* or *survival* of callosal axons, or promote asymmetric callosal axonal *pruning* later in development.

4.4. Are FT effects on asymmetry organizational effects?

These results also raise the question as to whether FT effects on isthmus asymmetry actually reflect organizational effects on the brain prenatally, rather than activational effects occurring after birth? For this question, we refer to 5 main criteria to define 'organizational effects' (Phoenix et al., 1959). Organizational effects are (1) *permanent*, (2) *occur early in life* just before or after birth, (3) *occur during critical or sensitive periods of brain development*, (4) *imply structural changes in the brain*, and (5) *are asymmetric relative to the sexes* (e.g., androgens are needed for male development, while estrogens are not needed for normal female development). While this study cannot address all of these criteria, we can conclude that it fulfills the criteria of influencing structural changes in the brain. Studies later on in development will likely be able to answer whether such effects are permanent. Furthermore, past research can testify that such effects occur early in life just before or after birth.

The fetal brain is already asymmetrical (Geschwind and Levitsky, 1968; Witelson and Pallie, 1973; Wada et al., 1975; Chi et al., 1977; Witelson, 1987) and may reach that stage by 20–22 weeks gestation (Hering-Hanit et al., 2001). The macaque CC in particular, has all the fibers it needs around birth, and then goes through a process of postnatal axonal pruning (LaMantia and Rakic, 1990a). However, such postnatal pruning does not affect the basic topography of callosal connections, which are laid out in an adult-like pattern well before birth (Killackey and Chalupa, 1986; Dehay et al., 1988; Schwartz and Goldman-Rakic, 1991). Furthermore, it is also known from studies in rats that such periods in prenatal brain development are critical for establishing normative sexual dimorphism in the CC (Fitch et al., 1991). Therefore, given these developmental considerations, FT effects on CC asymmetry are likely to be organizational in nature. However, the current data cannot rule out other activational effects later

in development such as early postnatal surges of testosterone or current testosterone levels (Moffat et al., 1997; Neufang et al., 2009; Peper et al., 2009a) and other sources of variability such as growth trajectories which may be important factors to consider in future work (Giedd et al., 1996, 1999; Thompson et al., 2000; Shaw et al., 2007).

4.5. Downstream cognitive effects of FT induced rightward callosal asymmetry

The cognitive/functional significance of organizational FT effects specific to isthmus asymmetry are likely to be linked with the main regions it projects to; primary somatosensory cortex along the postcentral gyrus/central sulcus, posterior parietal cortex, and superior temporal regions. The parietal areas that this region projects to are also integrally involved in somatosensory processes and low-level mirroring of touch in others (Keysers et al., 2004; Blakemore et al., 2005), action-perception mirroring (Gazzola and Keysers, 2009), emotion recognition (Adolphs et al., 2000), empathy (Bufalari et al., 2007), mental imagery (Ruby and Decety, 2001) visuospatial cognition (Hanggi et al., 2008; Zacks, 2008) and attention (Corbetta et al., 2008). The areas of superior temporal cortex that the isthmus projects to are temporal language areas in Wernicke's area such as the planum temporale and Heschl's gyrus (Pandya et al., 1971). In these regions, males show increased leftward asymmetry of gray matter density (Good et al., 2001) and area measurements (Witelson and Pallie, 1973) as well as leftward asymmetry in arcuate fasciculus connectivity to frontal language areas such as Broca's area (Catani et al., 2007). These asymmetries may correspond to early anatomical differences that arise during neonatal development (Witelson and Pallie, 1973). Furthermore, post-mortem evidence suggests that decreasing isthmus projections may predict increases in size asymmetries of these areas (Aboitiz et al., 1992a,b).

It is particularly striking that the cognitive specializations of these isthmus projection regions are known to be linked to FT. Emotion recognition and visuospatial cognition are biased towards rightward asymmetry in the typically developing brain (Witelson, 1976; Adolphs et al., 2000), while language abilities tend to be predominantly biased towards leftward asymmetry, especially in males. FT affects the development of mental rotation ability in 7-year-old children (Grimshaw et al., 1995b). Similarly, increased FT is associated with increased right hemisphere specialization in emotion recognition (Grimshaw et al., 1995a). In our own work, we find that FT is also related to the development of similar constructs such as empathizing (Chapman et al., 2006; Knickmeyer et al., 2006) and systemizing (Auyeung et al., 2006). Increases in FT also predicts more masculinized patterns of lateralization of speech processing (Grimshaw et al., 1995a; Cohen-Bendahan et al., 2004) and decreased vocabulary development (Lutchmaya et al., 2002b).

The convergence of FT effects on both cognitive sexual dimorphisms in empathizing, systemizing, and language, along with organizational FT effects on callosal asymmetry is most likely not a coincidence. We suggest that the organizational effect of FT on rightward shifts in callosal asymmetry may predispose the brain towards developing cognitive sexual dimorphism in language processing, visuospatial cognition/systemizing and empathy. Future research should

focus on how organizational effects of FT on callosal asymmetry may mediate the later development of sexually dimorphic cognitive abilities.

4.6. Corpus callosum and FT in neurodevelopmental conditions

The current results of FT effects on CC asymmetry also relate to work on neurodevelopmental conditions such as autism spectrum conditions (ASC), where some aspects of typical sexual dimorphism at the cognitive level are more pronounced (Baron-Cohen, 2002; Baron-Cohen et al., 2005). Recently, we found that FT is related to quantitative variability in autistic traits in the general population (Auyeung et al., 2009). Individuals with ASC also have reduced 2D:4D digit ratios, a proxy marker for increased FT (Manning et al., 2001). FT is also related to other behaviors over the course of development that are central to autism, including eye contact at 12 months (Lutchmaya et al., 2002a), vocabulary size at 18–24 months (Lutchmaya et al., 2002b), spontaneous mentalizing and restricted interests at 48 months (Knickmeyer et al., 2005, 2006), and empathizing and systemizing at 6–9 years of age (Auyeung et al., 2006; Chapman et al., 2006)

One of the most replicated neuroanatomical findings in autism is the distinct reduction in midsagittal callosal size (Egaas et al., 1995; Piven et al., 1997; Manes et al., 1999; Hardan et al., 2000; Boger-Megiddo et al., 2006; Kana et al., 2006, 2009; Vidal et al., 2006; Alexander et al., 2007; Just et al., 2007; Mason et al., 2008; Keary et al., 2009). Congenital conditions of complete or partial absence of callosal formation, known as agenesis of the CC, are also more common in autism (Paul et al., 2007) with the most well known case being the real-life 'Rainman', Kim Peek. Given the hypothesis that increased FT may increase callosal asymmetry, a similar mechanism may be at work in autism. No studies have yet investigated parasagittal CC asymmetry in autism, and such work will be vital in linking possible FT effects to the neurodevelopment of the CC in autism. In addition to the evidence from autism, future studies investigating disorders of sexual development and differentiation, such as Congenital Adrenal Hyperplasia, Androgen Insensitivity Syndrome, Turner's Syndrome, and Klinefelter's Syndrome are likely to shed considerable light on the relationship between early FT exposure and CC development.

4.7. Limitations and caveats

This study is the first to assess the direct effects of FT on *in vivo* CC size and asymmetry in humans. Although our sample size is relatively small, we were nevertheless able to identify robust effects of FT on the isthmus region of the CC and these results held after Bonferroni corrections for multiple comparisons. In regards to the null effects found in this study, one criticism could be whether we had enough power to detect smaller effect sizes. This is an important caveat and the results reported here require independent replication with larger sample sizes to determine whether sample size and power may be an issue.

It has also been suggested in the past that the resolution of MRI might not be able to detect the few millimeters of difference that post-mortem studies of the CC are able to

detect (Witelson, 1991; Witelson and Goldsmith, 1991). However, the advance in imaging technology since the early 1990s, when these statements were made, renders this a moot point. In our study, the native resolution of our images was isotropic 1 mm voxel sizes, thus enabling very small differences to be detected.

Finally, we acknowledge that the inferences of the current study are limited to males and the developmental time-point of 8–11 years of age. FT is harder to measure in females due to lower levels and less variability. This consideration might limit the ability to test whether similar effects of FT on the CC in females will be apparent in sample sizes as small as the current study. Testing this hypothesis in females will be important to examine, but is likely to require a far greater sample size. In future studies, it will also be important to investigate these questions at different time points in development. Longitudinal studies that assess both the organizational effects of FT on CC development and any interactions with 'activational' effects of testosterone later in development (Moffat et al., 1997) will be better able to answer such questions.

5. Conclusions

The current study is the first investigation of whether FT exposure influences the size and asymmetry of the human CC. This work complements the long-standing animal work which demonstrates that FT plays a crucial organizational role in neural sexual dimorphism and asymmetry (Beach, 1948; Phoenix et al., 1959; Arnold and Breedlove, 1985). First, we have shown that there was no relationship between FT exposure and midsagittal CC size. However, we found significant relationships between FT and callosal asymmetry. Previous predictions about asymmetry and FT in the brain by Geschwind (Geschwind and Galaburda, 1985a, 1985b, 1987) and Witelson (Witelson, 1991; Witelson and Nowakowski, 1991) converge and the current study shows that FT is a likely mechanism shaping a posterior section of the callosum, the isthmus, towards rightward asymmetry. The isthmus projects predominantly to parietal and superior temporal regions and may be involved in facilitating specialized functions of these regions such as empathy, systemizing, and language. The effects of FT on callosal asymmetry may also reflect early organizational effects on fetal brain development. However, future work contrasting the effects of FT and activational effects of testosterone later on in development are needed. Future work should also investigate whether FT effects on callosal asymmetry are indicative of an underlying mechanism related to neuroprotection. We conclude by pointing towards translational work in neurodevelopmental conditions, such as autism spectrum conditions, where FT and callosal development may be key neurobiological mechanisms (Baron-Cohen et al., 2005).

Conflict of interest statement

ETB is employed half-time by the University of Cambridge and half-time by GlaxoSmithKline plc. None of the other authors have any other biomedical financial interests or potential conflicts of interest.

Acknowledgments

LRC was supported by the Gates Cambridge Scholarship Trust. MVL was supported by the Shirley Foundation and the Cambridge Overseas Trust. This study was funded by a program grant from the MRC (UK) to SBC. FT assays were made possible by a grant to SBC from the Nancy Lurie Marks Family Foundation. We are grateful to Gerald Hackett and Kevin Taylor for their role in the Cambridge Fetal Testosterone Project over many years. We also thank the families who have taken part in this longitudinal study. Finally, we thank Matthew Belmonte for his comments regarding this manuscript, Svetlana Lutchmaya and Rebecca Knickmeyer for their contribution to recruiting this sample, and Melissa Hines for valuable discussions. This study was carried out in association with the NIHR CLAHRC for Cambridgeshire and Peterborough NHS Foundation Trust.

References

- Aboitiz, F., Scheibel, A.B., Fisher, R.S., Zaidel, E., 1992a. Fiber composition of the human corpus callosum. *Brain Res.* 598, 143–153.
- Aboitiz, F., Scheibel, A.B., Zaidel, E., 1992b. Morphometry of the Sylvian fissure and the corpus callosum, with emphasis on sex differences. *Brain* 115, 1521–1541.
- Adolphs, R., Damasio, H., Tranel, D., Cooper, G., Damasio, A.R., 2000. A role for somatosensory cortices in the visual recognition of emotion as revealed by three-dimensional lesion mapping. *J. Neurosci.* 20, 2683–2690.
- Alexander, A.L., Lee, J.E., Lazar, M., Boudos, R., DuBray, M.B., Oakes, T.R., Miller, J.N., Lu, J., Jeong, E.K., McMahon, W.M., Bigler, E.D., Lainhart, J.E., 2007. Diffusion tensor imaging of the corpus callosum in autism. *Neuroimage* 34, 61–73.
- Allen, L.S., Richey, M.F., Chai, Y.M., Gorski, R.A., 1991. Sex differences in the corpus callosum of the living human being. *J. Neurosci.* 11, 933–942.
- Arnold, A.P., Breedlove, S.M., 1985. Organizational and activational effects of sex steroids on brain and behavior: a reanalysis. *Horm. Behav.* 19, 469–498.
- Auyeung, B., Baron-Cohen, S., Chapman, E., Knickmeyer, R., Taylor, K., Hackett, G., 2006. Foetal testosterone and the child systemizing quotient. *Eur. J. Endocrinol.* 155, S123–S130.
- Auyeung, B., Baron-Cohen, S., Ashwin, E., Knickmeyer, R., Taylor, K., Hackett, G., 2009. Fetal testosterone and autistic traits. *Br. J. Psychol.* 100, 1–22.
- Baron-Cohen, S., 2002. The extreme male brain theory of autism. *Trends Cogn. Sci.* 6, 248–254.
- Baron-Cohen, S., Lutchmaya, S., Knickmeyer, R., 2004. *Prenatal Testosterone in Mind*. MIT Press, Cambridge, MA.
- Baron-Cohen, S., Knickmeyer, R.C., Belmonte, M.K., 2005. Sex differences in the brain: implications for explaining autism. *Science* 310, 819–823.
- Beach, F.A., 1948. *Hormones and Behavior*. Harper and Row (Hoeber), New York.
- Bean, R.B., 1906. Some racial peculiarities of the negro brain. *Am. J. Anat.* 5, 353–415.
- Berberi, A.S., Fitch, R.H., Ralphe, D.L., Denenberg, J.O., Friedrich Jr., V.L., Denenberg, V.H., 1988. Corpus callosum: region-specific effects of sex, early experience and age. *Brain Res.* 438, 216–224.
- Bishop, K.M., Wahlsten, D., 1997. Sex differences in the human corpus callosum: myth or reality? *Neurosci. Biobehav. Rev.* 21, 581–601.
- Blakemore, S.J., Bristow, D., Bird, G., Frith, C., Ward, J., 2005. Somatosensory activations during the observation of touch and a case of vision-touch synaesthesia. *Brain* 128, 1571–1583.

- Boger-Megiddo, I., Shaw, D.W., Friedman, S.D., Sparks, B.F., Artru, A.A., Giedd, J.N., Dawson, G., Dager, S.R., 2006. Corpus callosum morphometrics in young children with autism spectrum disorder. *J. Autism Dev. Disord.* 36, 733–739.
- Broca, P., 1861. Sur le volume et la forme du cerveau suivant les individus et suivant les races. *Bull. Soc. Anthropol.* 2, 139–207.
- Bufalari, I., Aprile, T., Avenanti, A., Di Russo, F., Aglioti, S.M., 2007. Empathy for pain and touch in the human somatosensory cortex. *Cereb. Cortex* 17, 2553–2561.
- Byne, W., Bleier, R., Houston, L., 1988. Variations in human corpus callosum do not predict gender: a study using magnetic resonance imaging. *Behav. Neurosci.* 102, 222–227.
- Catani, M., Allin, M.P., Husain, M., Pugliese, L., Mesulam, M.M., Murray, R.M., Jones, D.K., 2007. Symmetries in human brain language pathways correlate with verbal recall. *Proc. Natl. Acad. Sci. U.S.A.* 104, 17163–17168.
- Chapman, E., Baron-Cohen, S., Auyeung, B., Knickmeyer, R., Taylor, K., Hackett, G., 2006. Fetal testosterone and empathy: evidence from the empathy quotient (EQ) and the “reading the mind in the eyes” test. *Soc. Neurosci.* 1, 135–148.
- Chi, J.G., Dooling, E.C., Gilles, F.H., 1977. Left–right asymmetries of the temporal speech areas of the human fetus. *Arch. Neurol.* 34, 346–348.
- Clarke, S., Kraftsik, R., Van der Loos, H., Innocenti, G.M., 1989. Forms and measures of adult and developing human corpus callosum: is there sexual dimorphism? *J. Comp. Neurol.* 280, 213–230.
- Cohen-Bendahan, C.C., Buitelaar, J.K., van Goozen, S.H., Cohen-Kettenis, P.T., 2004. Prenatal exposure to testosterone and functional cerebral lateralization: a study in same-sex and opposite-sex twin girls. *Psychoneuroendocrinology* 29, 911–916.
- Corbetta, M., Patel, G., Shulman, G.L., 2008. The reorienting system of the human brain: from environment to theory of mind. *Neuron* 58, 306–324.
- de Lacoste, M.C., Holloway, R.L., Woodward, D.J., 1986. Sex differences in the fetal human corpus callosum. *Hum. Neurobiol.* 5, 93–96.
- Dehay, C., Kennedy, H., Bullier, J., Berland, M., 1988. Absence of interhemispheric connections of area 17 during development in the monkey. *Nature* 331, 348–350.
- DeLacoste-Utamsing, C., Holloway, R.L., 1982. Sexual dimorphism in the human corpus callosum. *Science* 216, 1431–1432.
- Egaas, B., Courchesne, E., Saitoh, O., 1995. Reduced size of corpus callosum in autism. *Arch. Neurol.* 52, 794–801.
- Fitch, R.H., Cowell, P.E., Schrott, L.M., Denenberg, V.H., 1991. Corpus callosum: demasculinization via perinatal anti-androgen. *Int. J. Dev. Neurosci.* 9, 35–38.
- Fleming, D.E., Anderson, R.H., Rhees, R.W., Kinghorn, E., Bakaitis, J., 1986. Effects of prenatal stress on sexually dimorphic asymmetries in the cerebral cortex of the male rat. *Brain Res. Bull.* 16, 395–398.
- Gazzola, V., Keysers, C., 2009. The observation and execution of actions share motor and somatosensory voxels in all tested subjects: single-subject analyses of unsmoothed fMRI data. *Cereb. Cortex* 19, 1239–1255.
- Geschwind, N., Behan, P., 1982. Left-handedness: association with immune disease, migraine, and developmental learning disorder. *Proc. Natl. Acad. Sci. U.S.A.* 79, 5097–5100.
- Geschwind, N., Galaburda, A.M., 1985a. Cerebral lateralization. Biological mechanisms, associations, and pathology: I. A hypothesis and a program for research. *Arch. Neurol.* 42, 428–459.
- Geschwind, N., Galaburda, A.M., 1985b. Cerebral lateralization. Biological mechanisms, associations, and pathology: II. A hypothesis and a program for research. *Arch. Neurol.* 42, 521–552.
- Geschwind, N., Galaburda, A.M., 1987. *Cerebral Lateralization: Biological Mechanisms, Associations, and Pathology*. MIT Press, Cambridge, MA.
- Geschwind, N., Levitsky, W., 1968. Human brain: left–right asymmetries in temporal speech region. *Science* 161, 186–187.
- Giedd, J.N., Snell, J.W., Lange, N., Rajapakse, J.C., Casey, B.J., Kozuch, P.L., Vaituzis, A.C., Vauss, Y.C., Hamburger, S.D., Kaysen, D., Rapoport, J.L., 1996. Quantitative magnetic resonance imaging of human brain development: ages 4–18. *Cereb. Cortex* 6, 551–560.
- Giedd, J.N., Blumenthal, J., Jeffries, N.O., Castellanos, F.X., Liu, H., Zijdenbos, A., Paus, T., Evans, A.C., Rapoport, J.L., 1999. Brain development during childhood and adolescence: a longitudinal MRI study. *Nat. Neurosci.* 2, 861–863.
- Going, J.J., Dixson, A., 1990. Morphometry of the adult human corpus callosum: lack of sexual dimorphism. *J. Anat.* 171, 163–167.
- Good, C.D., Johnsrude, I., Ashburner, J., Henson, R.N., Friston, K.J., Frackowiak, R.S., 2001. Cerebral asymmetry and the effects of sex and handedness on brain structure: a voxel-based morphometric analysis of 465 normal adult human brains. *Neuroimage* 14, 685–700.
- Goy, R.W., McEwen, B.S., 1980. *Sexual Differentiation of the Brain*. MIT Press, Cambridge Massachusetts.
- Grimshaw, G.M., Bryden, M.P., Finegan, J.K., 1995a. Relations between prenatal testosterone and cerebral lateralization in children. *Neuropsychology* 9, 68–79.
- Grimshaw, G.M., Sitarenios, G., Finegan, J.A., 1995b. Mental rotation at 7 years: relations with prenatal testosterone levels and spatial play experiences. *Brain Cogn.* 29, 85–100.
- Hanggi, J., Buchmann, A., Mondadori, C.R., Henke, K., Jancke, L., Hock, C., 2008. Sexual dimorphism in the parietal substrate associated with visuospatial cognition independent of general intelligence. *J. Cogn. Neurosci.*, doi:10.1162/jocn.2008.21175.
- Hardan, A.Y., Minshew, N.J., Keshavan, M.S., 2000. Corpus callosum size in autism. *Neurology* 55, 1033–1036.
- Hering-Hanit, R., Achiron, R., Lipitz, S., Achiron, A., 2001. Asymmetry of fetal cerebral hemispheres: in utero ultrasound study. *Arch. Dis. Child Fetal Neonatal Ed.* 85, F194–F196.
- Hines, M., 2004. *Brain Gender*. Oxford University Press, New York.
- Hofer, S., Frahm, J., 2006. Topography of the human corpus callosum revisited—comprehensive fiber tractography using diffusion tensor magnetic resonance imaging. *Neuroimage* 32, 989–994.
- Holloway, R.L., de Lacoste, M.C., 1986. Sexual dimorphism in the human corpus callosum: an extension and replication study. *Hum. Neurobiol.* 5, 87–91.
- Holloway, R.L., Anderson, P.J., Defendini, R., Harper, C., 1993. Sexual dimorphism of the human corpus callosum from three independent samples: relative size of the corpus callosum. *Am. J. Phys. Anthropol.* 92, 481–498.
- Just, M.A., Cherkassky, V.L., Keller, T.A., Kana, R.K., Minshew, N.J., 2007. Functional and anatomical cortical underconnectivity in autism: evidence from an fMRI study of an executive function task and corpus callosum morphometry. *Cereb. Cortex* 17, 951–961.
- Kana, R.K., Keller, T.A., Cherkassky, V.L., Minshew, N.J., Just, M.A., 2006. Sentence comprehension in autism: thinking in pictures with decreased functional connectivity. *Brain* 129, 2484–2493.
- Kana, R.K., Keller, T.A., Cherkassky, V.L., Minshew, N.J., Just, M.A., 2009. Atypical frontal-posterior synchronization of Theory of Mind regions in autism during mental state attribution. *Soc. Neurosci.* 4, 135–152.
- Keary, C.J., Minshew, N.J., Bansal, R., Goradia, D., Fedorov, S., Keshavan, M.S., Hardan, A.Y., 2009. Corpus callosum volume and neurocognition in Autism. *J. Autism Dev. Disord.* 39, 834–841.
- Keysers, C., Wicker, B., Gazzola, V., Anton, J.L., Fogassi, L., Gallese, V., 2004. A touching sight: SII/PV activation during the observation and experience of touch. *Neuron* 42, 335–346.
- Killackey, H.P., Chalupa, L.M., 1986. Ontogenetic change in the distribution of callosal projection neurons in the postcentral gyrus of the fetal rhesus monkey. *J. Comp. Neurol.* 244, 331–348.
- Killeen, P.R., 2005. An alternative to null-hypothesis significance tests. *Psychol. Sci.* 16, 345–353.

- Knickmeyer, R., Baron-Cohen, S., Raggatt, P., Taylor, K., 2005. Foetal testosterone, social relationships, and restricted interests in children. *J. Child Psychol. Psychiatry* 46, 198–210.
- Knickmeyer, R., Baron-Cohen, S., Raggatt, P., Taylor, K., Hackett, G., 2006. Fetal testosterone and empathy. *Horm. Behav.* 49, 282–292.
- Kujawa, K.A., Emeric, E., Jones, K.J., 1991. Testosterone differentially regulates the regenerative properties of injured hamster facial motoneurons. *J. Neurosci.* 11, 3898–3906.
- LaMantia, A.S., Rakic, P., 1990a. Axon overproduction and elimination in the corpus callosum of the developing rhesus monkey. *J. Neurosci.* 10, 2156–2175.
- LaMantia, A.S., Rakic, P., 1990b. Cytological and quantitative characteristics of four cerebral commissures in the rhesus monkey. *J. Comp. Neurol.* 291, 520–537.
- Luders, E., Narr, K.L., Zaidel, E., Thompson, P.M., Jancke, L., Toga, A.W., 2006. Parasagittal asymmetries of the corpus callosum. *Cereb. Cortex* 16, 346–354.
- Lutchmaya, S., Baron-Cohen, S., Raggatt, P., 2002a. Foetal testosterone and eye contact in 12 month-old infants. *Inf. Behav. Dev.* 25, 327–335.
- Lutchmaya, S., Baron-Cohen, S., Raggatt, P., 2002b. Foetal testosterone and vocabulary size in 18- and 24-month old infants. *Inf. Behav. Dev.* 24, 418–424.
- MacLusky, N.J., Naftolin, F., 1981. Sexual differentiation of the central nervous system. *Science* 211, 1294–1302.
- Mall, F.P., 1909. On several anatomical characters of the human brain, said to vary according to race and sex, with special reference to the weight of the frontal lobe. *Am. J. Anat.* 9, 1–32.
- Manes, F., Piven, J., Vrancic, D., Nanclares, V., Plebst, C., Starkstein, S.E., 1999. An MRI study of the corpus callosum and cerebellum in mentally retarded autistic individuals. *J. Neuropsychiatry Clin. Neurosci.* 11, 470–474.
- Manning, J.T., Baron-Cohen, S., Wheelwright, S., Sanders, G., 2001. The 2nd to 4th digit ratio and autism. *Dev. Med. Child Neurol.* 43, 160–164.
- Mason, R.A., Williams, D.L., Kana, R.K., Minshew, N., Just, M.A., 2008. Theory of mind disruption and recruitment of the right hemisphere during narrative comprehension in autism. *Neuropsychologia* 46, 269–280.
- Moffat, S.D., Hampson, E., Wickett, J.C., Vernon, P.A., Lee, D.H., 1997. Testosterone is correlated with regional morphology of the human corpus callosum. *Brain Res.* 767, 297–304.
- Neufang, S., Specht, K., Hausmann, M., Gunturkun, O., Herpertz-Dahlmann, B., Fink, G.R., Konrad, K., 2009. Sex differences and the impact of steroid hormones on the developing human brain. *Cereb. Cortex* 19, 464–473.
- Pandya, D.N., Karol, E.A., Heilbron, D., 1971. The topographical distribution of interhemispheric projections in the corpus callosum of the rhesus monkey. *Brain Res.* 32, 31–43.
- Paul, L.K., Brown, W.S., Adolphs, R., Tyszka, J.M., Richards, L.J., Mukherjee, P., Sherr, E.H., van Baal, G.C., van Leeuwen, M., van den Berg, S.M., Delemarre-Van de Waal, H.A., Boomsma, D.I., Kahn, R.S., Hulshoff Pol, H.E., 2007. Agenesis of the corpus callosum: genetic, developmental and functional aspects of connectivity. *Nat. Rev. Neurosci.* 8, 287–299.
- Peper, J.S., Brouwer, R.M., Schnack, H.G., 2009a. Sex steroids and brain structure in pubertal boys and girls. *Psychoneuroendocrinology* 34, 332–342.
- Peper, J.S., Brouwer, R.M., van Baal, G.C., Schnack, H.G., van Leeuwen, M., Boomsma, D.I., Kahn, R.S., Hulshoff Pol, H.E., 2009b. Does having a twin brother make for a bigger brain? *Eur. J. Endocrinol.* 160, 739–746.
- Phoenix, C.H., Goy, R.W., Gerall, A.A., Young, W.C., 1959. Organizing action of prenatally administered testosterone propionate on the tissues mediating mating behavior in the female guinea pig. *Endocrinology* 65, 369–382.
- Piven, J., Bailey, J., Ranson, B.J., Arndt, S., 1997. An MRI study of the corpus callosum in autism. *Am. J. Psychiatry* 154, 1051–1056.
- Ruby, P., Decety, J., 2001. Effect of subjective perspective taking during simulation of action: a PET investigation of agency. *Nat. Neurosci.* 4, 546–550.
- Schwartz, M.L., Goldman-Rakic, P.S., 1991. Prenatal specification of callosal connections in rhesus monkey. *J. Comp. Neurol.* 307, 144–162.
- Shaw, P., Kabani, N.J., Lerch, J.P., Eckstrand, K., Lenroot, R., Gogtay, N., Greenstein, D., Clasen, L., Evans, A., Rapoport, J.L., Giedd, J.N., Wise, S.P., 2007. Neurodevelopmental trajectories of the human cerebral cortex. *J. Neurosci.* 28, 3586–3594.
- Sowell, E.R., Peterson, B.S., Kan, E., Woods, R.P., Yoshii, J., Bansal, R., Xu, D., Zhu, H., Thompson, P.M., Toga, A.W., 2007. Sex differences in cortical thickness mapped in 176 healthy individuals between 7 and 87 years of age. *Cereb. Cortex* 17, 1550–1560.
- Sperry, R., 1982. Some effects of disconnecting the cerebral hemispheres. *Science* 217, 1223–1226.
- Stewart, J., Kolb, B., 1988. The effects of neonatal gonadectomy and prenatal stress on cortical thickness and asymmetry in rats. *Behav. Neural Biol.* 49, 344–360.
- Thompson, P.M., Giedd, J.N., Woods, R.P., MacDonald, D., Evans, A.C., Toga, A.W., 2000. Growth patterns in the developing brain detected by using continuum mechanical tensor maps. *Nature* 404, 190–193.
- Tomasch, J., 1954. Size, distribution, and number of fibres in the human corpus callosum. *Anat. Rec.* 119, 119–135.
- Vidal, C.N., Nicolson, R., DeVito, T.J., Hayashi, K.M., Geaga, J.A., Drost, D.J., Williamson, P.C., Rajakumar, N., Sui, Y., Dutton, R.A., Toga, A.W., Thompson, P.M., 2006. Mapping corpus callosum deficits in autism: an index of aberrant cortical connectivity. *Biol. Psychiatry* 60, 218–225.
- Wada, J.A., Clarke, R., Hamm, A., 1975. Cerebral hemispheric asymmetry in humans. Cortical speech zones in 100 adults and 100 infant brains. *Arch. Neurol.* 32, 239–246.
- Ward, I.L., Weisz, J., 1980. Maternal stress alters plasma testosterone in fetal males. *Science* 207, 328–329.
- Witelson, D.F., 1976. Sex and the single hemisphere: specialization of the right hemisphere for spatial processing. *Science* 193, 425–427.
- Witelson, S.F., 1985. The brain connection: the corpus callosum is larger in left-handers. *Science* 229, 665–668.
- Witelson, S.F., 1987. Neurobiological aspects of language in children. *Child Dev.* 58, 653–688.
- Witelson, S.F., 1989. Hand and sex differences in the isthmus and genu of the human corpus callosum. A postmortem morphological study. *Brain* 112, 799–835.
- Witelson, S.F., 1991. Neural sexual mosaicism: sexual differentiation of the human temporo-parietal region for functional asymmetry. *Psychoneuroendocrinology* 16, 131–153.
- Witelson, S.F., Goldsmith, C.H., 1991. The relationship of hand preference to anatomy of the corpus callosum in men. *Brain Res.* 545, 175–182.
- Witelson, S.F., Nowakowski, R.S., 1991. Left out axons make men right: a hypothesis for the origin of handedness and functional asymmetry. *Neuropsychologia* 29, 327–333.
- Witelson, S.F., Pallie, W., 1973. Left hemisphere specialization for language in the newborn. Neuroanatomical evidence of asymmetry. *Brain* 96, 641–646.
- Yu, W.H., Srinivasan, R., 1981. Effect of testosterone and 5 alpha-dihydrotestosterone on regeneration of the hypoglossal nerve in rats. *Exp. Neurol.* 71, 431–435.
- Zacks, J.M., 2008. Neuroimaging studies of mental rotation: a meta-analysis and review. *J. Cogn. Neurosci.* 20, 1–19.
- Zimmerberg, B., Scalzi, L.V., 1989. Commissural size in neonatal rats: effects of sex and prenatal alcohol exposure. *Int. J. Dev. Neurosci.* 7, 81–86.